

# Biomedical Ultrasound: Fundamentals of Imaging and Micromachined Transducers

Prof. Karla P. Mercado-Shekhar, Prof. Himanshu Shekhar, Prof. Hardik Jeetendra Pandya

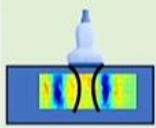

IIT Gandhinagar, IISc Bangalore

Lecture: 49

## Shear Wave Imaging

Hello. Welcome to the lecture on Introduction to Shear Wave Imaging. So today I will be describing different shear wave imaging methods that are used clinically. So here are two methods that I have in this table. We first have a set of shear wave elastography methods where the excitation to produce the shear wave is called the acoustic radiation force. And we will look more into that in the subsequent slides.

### Shear wave imaging methods

Method	Excitation Method	Technique	Measurements
	Acoustic Radiation Force Impulse (ARFI)	Point Shear Wave Speed Measurement	<ul style="list-style-type: none"><li>Shear Wave Speed (m/s)</li><li>Young's Modulus (kPa)</li></ul>
		Shear Wave Speed Imaging	
	External Mechanical Vibration (EMV)	Transient Elastography	<ul style="list-style-type: none"><li>Young's Modulus (kPa)</li></ul>

There are two techniques that I will also focus on, point shear wave speed measurement and 2D shear wave speed imaging. And using these two techniques, you will be able to measure the shear wave speed at specific regions of interest in the tissue and the Young's modulus.

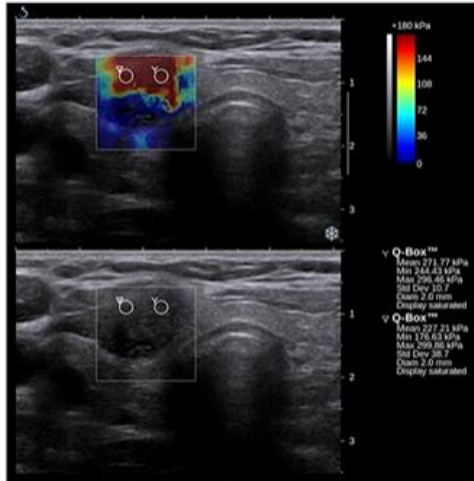
The second set of techniques that we will discuss today is called transient elastography. And in this technique, the excitation method would be a mechanical vibration system that will be used to generate shear waves. Now this technique can help you measure the Young's modulus. So what we will do is we will look over the principles behind these two techniques, the advantage and limitations of the techniques, as well as their clinical applications.

In a previous lecture, we had discussed different types of ultrasound waves, and one of these waves are shear waves. So if you remember this schematic here, this animation shows what the shear wave propagation looks like, where you have particles in a tissue

that will oscillate perpendicular to the direction of the wave propagation. And if we have several assumptions, such as an incompressible medium, elastic, isotropic, then we can be able to calculate the shear modulus using the following equation here,

$$G = \rho c_s^2$$

## Shear wave elastography (SWE)



[https://commons.wikimedia.org/wiki/File:Thyroid\\_SSI\\_Szczebanek-Parulska\\_et\\_al\\_2013\\_papillary\\_thyroid\\_carcinoma\\_elastography.png](https://commons.wikimedia.org/wiki/File:Thyroid_SSI_Szczebanek-Parulska_et_al_2013_papillary_thyroid_carcinoma_elastography.png) Ewelina Szczebanek-Parulska, Kosma Wolinski, Adam Stangierski, Edyta Gurgul, Maciej Biczysko, Przemyslaw Majewski, Magdalena Rewaj, Łosyk, Marek Ruchala, CC BY 3.0  
<<https://creativecommons.org/licenses/by/3.0/>>, via Wikimedia Commons

## Shear wave propagation



Animation by Dan Russell are licensed under a CC BY-NC-ND 4.0 International License. [https://www.acs.psu.edu/drussell/Demos/waves\\_intro/waves\\_intro.html](https://www.acs.psu.edu/drussell/Demos/waves_intro/waves_intro.html)

$$G = \rho \times c_s^2$$

- Shear wave speed  $c_s$ : 1 – 10 m/s
- Shear modulus,  $G$ :  $10^3 - 10^8$  Pa (1- 100 kPa)
- Young's modulus,  $E = 3 \times G$



In tissue, the shear wave speed ranges on the order of 1 to 10 m/s. And the shear modulus ranges on the orders of 1 to 100 kPa. So the nice thing about measuring the shear modulus with respect to mechanical property imaging is that there's a wide range of shear modulus within tissue. That way, you will be able to differentiate between different tissue types, as well as be able to differentiate between healthy or diseased tissue quite well. Now, if you move further, you can also estimate the Young's modulus, which is denoted by this parameter E, and that equals 3 times the shear modulus.

An example of an elastography image is shown here on the left, where we have the B-mode image in the bottom, and a color map of the elasticity estimates. Now, the scale bar is in terms of the Young's modulus. Wherein red means that it has a higher Young's modulus, the tissue is more stiff, and blue means that the tissue is softer, so it has a lower Young's modulus. So we will go over how these images are being created in elastography.

I have described acoustic radiation force, and this is a way to excite the tissue to be able to induce these shear waves. Acoustic radiation force is a body force that is in the direction of the acoustic wave propagation, and it's caused by transfer of momentum from the acoustic wave to the medium. So in an absorbing medium and assuming that within

that region there is a plane wave propagation, then the acoustic radiation force  $F$  is, the power that's absorbed by the medium at a given spatial location divided by the longitudinal sound speed,  $C$ . And that equals to two times the acoustic absorption coefficient of the tissue times the temporal average intensity at a given spatial location in the tissue. So the intensity that we're talking about here is the spatial peak temporal average intensity. So this is the intensity that helps determine the acoustic radiation force strength.

$$F = \frac{W_{abs}}{c} = \frac{2 * \alpha * I}{c}$$

## Excitation: Acoustic radiation force

- Body force in the direction of acoustic wave propagation
- Caused by transfer of momentum from acoustic wave to medium
- In an absorbing medium and assuming a plane wave

**Acoustic radiation force,  $F$ :**

$$F = \frac{W_{abs}}{c} = \frac{2 \times \alpha \times I}{c}$$

- $W_{abs}$  = power absorbed by medium at given spatial location ( $W/m^3$ )
- $c$  = longitudinal speed of sound (m/s)
- $\alpha$  = acoustic absorption coefficient (np/m)
- $I$  = temporal average intensity at a given spatial location ( $W/cm^2$ )

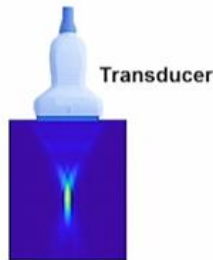And typically in elastography, acoustic radiation force impulse is implemented. That's ARFI as an abbreviation. So the ARFI push pulse, as we say, is used to displace the tissue, typically on the order of 10 to 20 microns. So these are very small displacements. And what is needed to produce this ARFI is a really high intensity pulse.

So with an  $I_{SPTA}$  typically on the order of 1,000 to 1,400  $W/cm^2$ . To be able to produce this type of high intensity pulse, you would also need a focused beam. So here at the bottom schematic, I am showing the beam profile of a focused pulse that is being transmitted by a linear array transducer.

## Acoustic radiation force impulse (ARFI)

- **ARFI “push pulse”:**
- Used to displace tissue  $\sim 10\text{--}20\ \mu\text{m}$

High-intensity pulse $I_{\text{SPTA}}$ : 1000 – 1400 W/cm <sup>2</sup>	High-performance power electronics
Focused pulse	Long-duration pulse 500 – 1,000 cycles, 0.1 – 0.5 ms

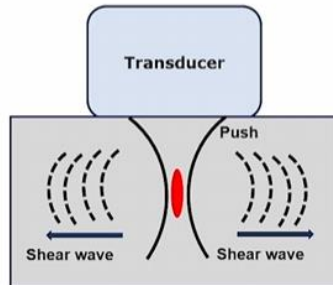


So you can see this is a color map scale in which yellow indicates higher intensity, and blue indicates low intensity. So you can see that at the focus there is really high intensity of the wave. And what's needed to be able to produce this focused beam is high performance power electronics. So you really need electronics that will enable you to be able to generate these radiation force impulse. Also, since the intensity is important for producing this radiation force, typically long duration pulses are used, typically on the orders of 500 to 1,000 cycles.

When we talk about time or pulse durations, that's of about 0.1 to 0.5 milliseconds. So these pulses are typically much longer than what is used in conventional B mode ultrasound, which utilizes about two cycles. Now, the ARFI-based shear wave elastography workflow consists of the following, where first, this ARFI excitation is used to displace the tissue. Next, the shear wave propagates laterally away from the site of this ARFI excitation. So here I show a schematic of what goes on when we induce the shear wave.

## ARFI-based SWE workflow

1. ARFI causes tissue to displace
2. Shear wave propagates laterally away from the site of ARFI excitation



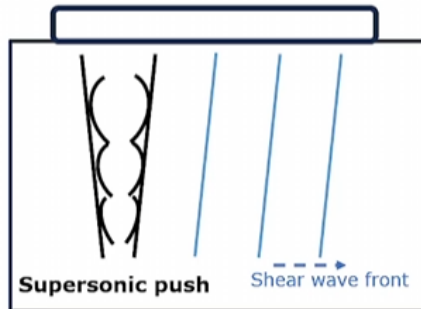
So first, we have our focused push, and at the site where I denote it as red is where the ARFI will be applied. And then because of that ARFI, the tissue will displace and then it will go back up to its original position. And because of that, a shear wave will then form that is traveling laterally from the site of ARFI excitation.

This shear wave will travel on both sides away from the ARFI excitation location. So this is similar to when you have a still pond and can think of the ARFI pulse as a drop of water. The shear waves are the ripples created when the drop of water goes onto the still pond. So what's going to be forming that ripples is actually a surface wave. But if you think of what goes on inside the tissue during ARFI excitation, a similar thing happens wherein a shear wave is emanating outside, away from the site of this ARFI excitation.

Now, one can also create what's called a near plane wave supersonic shear front. And this is a type of excitation that is used in a supersonic shear imaging. So what goes on here is that you have multiple focused push beams that are being sent at multiple axial depths. So in this image here, we have different push beams that are being excited at multiple axial depths, and that creates a supersonic push.

## Supersonic shear imaging

- **Excitation:** Create a near plane wave supersonic shear front by rapidly, successively focusing the push beam at multiple axial depths
- Shear waves propagating away from region of excitation sum constructively along a Mach cone, creating a cylindrical shear wave

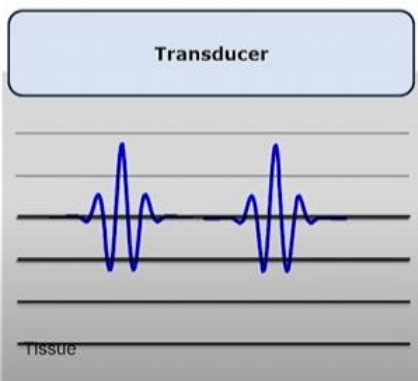


It creates shear waves that are propagating from the region of the excitation, and those shear waves sum constructively along a mach cone. That creates a cylindrical wave that then propagates along the axial depth of the tissue. So this blue indicates the shear wave front that is traveling away from the site of this supersonic push. And the nice thing about this supersonic push is that now you will be able to look into a two-dimensional view of the mechanical properties of the tissue. After the excitation is sent, you will then monitor the shear waves, and that's typically monitored using ultrasound pulse echo imaging.

Previously focused beams were used. Until recently, plane wave imaging has gained popularity to be able to monitor these fast-moving shear waves.

## Workflow

3. Shear wave is monitored by ultrasound pulse-echo imaging



- Plane wave imaging used to image at ultrafast (kHz) frame rates to capture fast-moving shear waves
- Angular compounding to improve spatial resolution



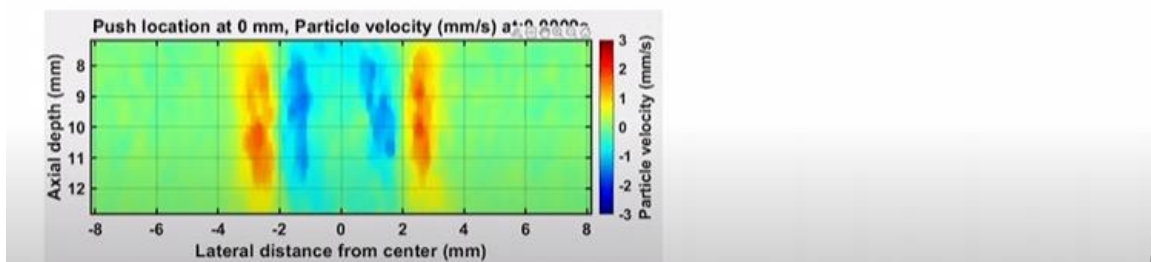
So what plane wave imaging does is it excites all the transducer elements, and then creates the plane wave that is then being used to assess all the regions of the tissue within the imaging field of view. So it utilizes ultra-fast frame rates, meaning that you use almost kilohertz ranges of frame rates. Compare that to conventional B-mode ultrasound, which is typically on order of 100 hertz. In this case, we can go up to 4,000 kHz or 4,000 kHz frame rates. And that allows us to capture these fast moving shear waves.

Typically, plane wave imaging doesn't have good spatial resolution. So what is typically being done is that you would angle the plane wave and sum all the echoes that are being received after plane wave excitation. And you do that after many angles. And the resulting images from these angles are then being summed together to form a final compounded image. So this is called angular plane wave compounding. And it has been used to improve the spatial resolution in plane wave imaging.

After you've obtained and tracked the shear wave as a function of time, now what you are doing when you're tracking the shear wave is you're taking snapshots of B-mode images, as a function of time. So you have this 3D data set, which corresponds to the lateral axial direction, also the time direction. In elastography terms, we call this in the slow time direction. And using this 3D data set, we will compute the tissue particle displacements or the velocities using a cross correlation algorithm or a spatial correlation speckle tracking algorithm that will allow us to monitor the particle displacements as the shear wave is propagating through the tissue. And so here in this GIF below, I show a propagating shear wave wherein the acoustic radiation force impulse was applied at the lateral location of zero millimeters.

## Workflow

4. Tissue particle displacements are computed using speckle-tracking algorithm
5. Compute speed of shear wave at each spatial location using kernel-based method (assume homogeneous material in each kernel)



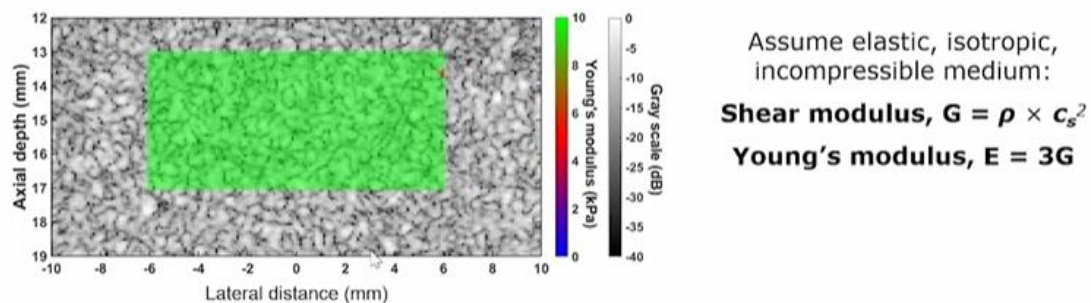
And after some time, there are two shear wave fronts that will be propagating alongside the lateral directions away from the site of excitation. So you see two shear wave fronts

that are moving to the left and to the right. Afterwards, you would look at each spatial location and compute the speed of the shear wave using some kernel-based methods. And typically, what is assumed in these small kernels, the material is homogeneous. So there are several kernel-based methods that you would use. In this lecture, I will just introduce you to the basic components of the elastography method, and you're welcome to look more into these kernel-based methods for computing the shear wave speed.

After you have measured the shear wave speed, you can also generate the shear modulus by using our equation, based on several assumptions of assuming that the material is elastic, isotropic, or incompressible. You can also compute the Young's modulus at each spatial location and eventually generate an image such as this.

## Workflow

6. Generate image of shear wave speed, shear modulus, or Young's modulus



So this is an image of a tissue-mimicking phantom. You can see that the B-mode, which is in grayscale, and the overlaid Young's modulus image in green. So in this image, we see that most of the tissue or the tissue-mimicking phantom is around 10 kPa.

For clinical applications, typically this shear wave elastography is used to assess breast, thyroid, liver, kidney, prostate, lymph nodes. So these are all assessments that are being done in the clinic today. You can also use it to monitor thermal ablation procedures if you're doing image-guided therapy. So here's just an example on the left of a breast tumor, where here on the left is a B-mode image. It's fairly challenging to see where the lesions are or the tumors are in this grayscale B-mode image.



## Clinical applications

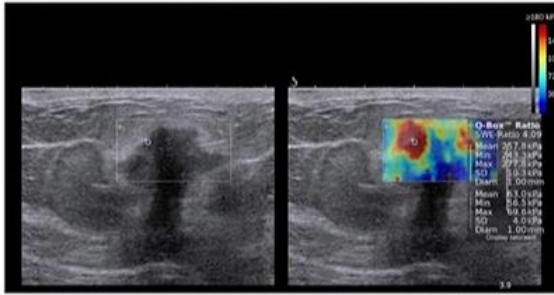


Figure from Sigrist, R.M.S., Liau, J., Kaffas, A.E., Chammas, M.C., Willmann, J.K. (2017). Ultrasound Elastography: Review of Techniques and Clinical Applications. *Theranostics*, 7(5), 1303-1329. <https://doi.org/10.7155/thno.18650>  
This is an open access article distributed under the terms of the Creative Commons Attribution (CC BY-NC) license (<https://creativecommons.org/licenses/by-nc/4.0/>).

- Detect breast cancer lesions
- Assess liver stiffness based on different pathologies, e.g., fibrosis and focal lesions
- Thyroid, kidney, prostate, lymph nodes
- Monitor thermal ablation procedures

But if you map the elastography here on the image to the right, you do the elastography, and map the Young's modulus using this color scale. Then you will be able to see exactly where the stiff regions are. And this stiff region would indicate the location of the tumors.

The advantages of shear wave elastography is that it provides quantitative estimates of the mechanical properties. You can also image deep in the tissue, almost several centimeters, and that depends on the frequency of the ultrasound. So basically, we know that there's a relationship between the frequency of sound and the penetration depth. So if you use higher frequency, then you would be able to image only at lower penetration depths compared to when you're using lower frequency. So typically, elastography is being done between 2 to 7 MHz ultrasound frequencies. And again, this depends on the application and which organ you're trying to image.

## Advantages and limitations of shear wave elastography

### Advantages:

- Quantitative
- Can image deep in tissue (several cm), depending on frequency

### Limitations:

- Assumption of elastic, isotropic, incompressible, homogeneous medium
- Requires high-end power electronics

### Active areas of research:

- Algorithms to estimate tissue viscoelasticity in real-time
- Account for boundary artifacts due to different tissue layers
- Anisotropic, heterogeneous tissues

Several limitations of shear wave elastographies are that it's based on assumptions of an elastic medium, isotropic, incompressible, and homogeneous. As we know, tissues are inherently viscoelastic and heterogeneous. So therefore, there are several active areas of research to try to develop algorithms that will be able to incorporate the viscoelastic, anisotropic, heterogeneous nature of tissues. Elastography also requires high-end power electronics. So specialized systems are needed to be able to produce this ARFI to be able to excite the tissue and generate shear waves. So there are some limitations based on accessibility due to this high-end power electronics.

Nonetheless, there are efforts on trying to make this system affordable. And also, some active areas of research include accounting for boundary artifacts that are around different tissue layers. As you can imagine, different boundaries can produce different ultrasound boundary effects, such as refraction, reflection, and so forth. So there are several algorithms that are being used to try to compensate for that or account for it.

In terms of the safety of ARFI-based imaging, since we are using long-duration pulses and high intensity, there would be some concerns with the bio-effects of these ARFI-based techniques.

## **Safety of ARFI-based imaging**

### **Safety metrics**

- Mechanical index (MI) – potential for inducing acoustic cavitation
- Thermal index (TI) – potential for tissue heating

### **ARFI methods**

- Pulse amplitudes ( $1.0 < MI < 1.9$ )
- Longer pulse durations (hundreds of cycles) than commonly used of diagnostic image
- Systems with ARFI-based elastography mode are designed to function within acceptable diagnostic imaging limits

### **ALARA (As Low As Reasonably Achievable) principle**

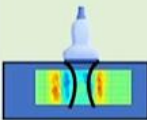

So I will just briefly introduce some of the safety metrics that are being used. And there is one lecture that is dedicated to safety in biomedical ultrasound. But the two metrics that I will briefly talk about are the mechanical index, which is the potential for inducing acoustic cavitation, that is MI, and the thermal index, which is the potential for tissue heating. So typically in the displays of ultrasound scanners, you will see both of these metrics, the MI and the TI. And that will help the clinician, or the sonographer to guide whether the ultrasound output is within these safety limits.

And so since ARFI methods use pulse amplitudes that are typically around 1 to 1.9 MI. ARFI methods use longer pulse durations, hundreds of cycles than commonly used in the diagnostic range. But systems with ARFI-based elastography, are designed to function

within these diagnostic limits. And thus far, there hasn't been any major adverse effects that have been reported with ARFI-based elastography. But keeping in mind that the sonographers always make sure that they follow the ALARA principle. ALARA meaning As Low As Reasonably Achievable.

Now for the second technique, the transient elastography.

### Shear wave imaging methods

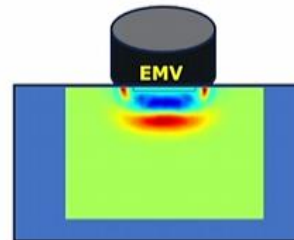
Method	Excitation Method	Technique	Measurements
 Shear Wave Imaging	Acoustic Radiation Force Impulse (ARFI)	Point Shear Wave Speed Measurement	<ul style="list-style-type: none"> <li>Shear Wave Speed (m/s)</li> <li>Young's Modulus (kPa)</li> </ul>
		Shear Wave Speed Imaging	
 Transient Elastography	External Mechanical Vibration (EMV)	Transient Elastography	<ul style="list-style-type: none"> <li>Young's Modulus (kPa)</li> </ul>

And the way the excitation is done is through an external mechanical vibration system. So it's another way to generate the shear wave. In comparison to ARFI-based systems, this is fairly low-cost and portable. You do not need a high-power electronic system to be able to generate the AFRI.

### Transient elastography

- Shear wave generation technique
  - External Mechanical Vibration (EMV)

Another way to generate shear wave	Low cost and portability
Deeper in tissue than ARFI-induced shear wave	Higher local displacements amplitudes
Requires less complex power system to operate	Simple to control frequency of mechanical vibration

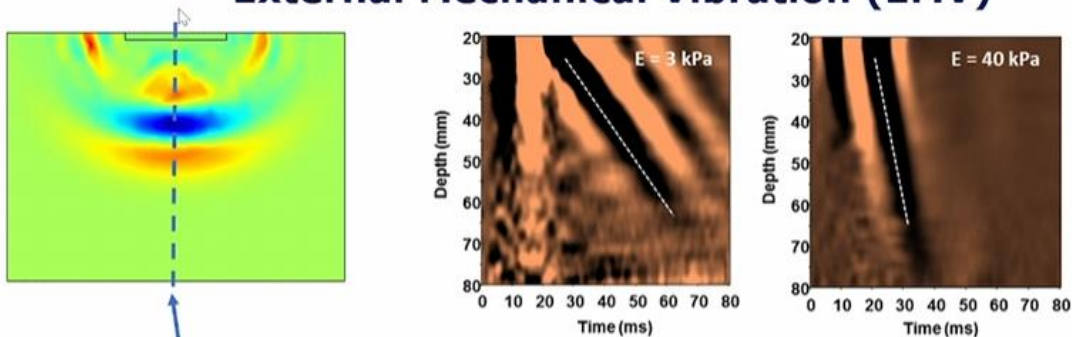


These mechanical vibration systems are affordable and quite low cost, and what you would need them for is to generate shear waves similar to what you are seeing in the

image above. You can see that the vibration is being done perpendicular to the tissue's surface right, and it's generating a wave that is propagating along the axial direction. So the nice thing about EMV is that you can dial it into specific vibration amplitudes, and this allows deeper penetration depths in tissue compared to ARFI induced shear wave, which is limited by the depth of penetration of the ultrasound. It has been found that EMV-based techniques can induce higher local displacement amplitudes, and it requires less complex power system to operate, and it's fairly simple to control the frequency of the mechanical vibration.

In the EMV technique, typically what is done is that you would monitor the longitudinal shear wave. So you would monitor the shear wave as it's propagating longitudinally or towards the direction of the transducer. And you would look at the shear wave at the zero lateral location.

## External Mechanical Vibration (EMV)



- Track shear wave along axial depth at one lateral location (1-D transient elastography)
- A-mode ultrasound is used to measure the shear wave speed
- Young's modulus  $E$  is calculated

[https://commons.wikimedia.org/wiki/File:VCTE\\_normal\\_and\\_cirrhotic\\_livers.tif](https://commons.wikimedia.org/wiki/File:VCTE_normal_and_cirrhotic_livers.tif) Slaurent73, CC BY-SA 4.0 <<https://creativecommons.org/licenses/by-sa/4.0/>>, via Wikimedia Commons



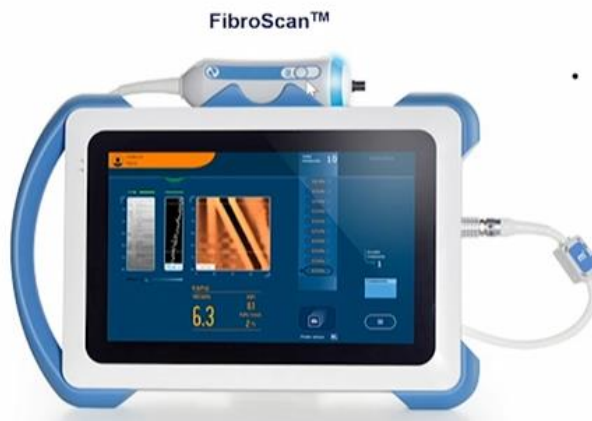So it's on axis of the beam. So you would track the shear wave along this axial depth at the one lateral location. This is typically known as 1D transient elastography. And A-mode ultrasound is used to measure the shear wave speed. So what you are looking here is that, if you have a material that is on the order of 3 kPa Young's modulus, and you would plot the A-mode signal along the depth as a function of the time or slow time. Now, this time here is different from the time that is used in the range equation. That time basically involves the creation of the depth axis. The time that you're displaying here is based on the frame rates or the pulse repetition frequency of the sound. So you're looking at the A-mode, you're sending. As the external mechanical vibration is operating, you can see that the shear wave is traveling along the depth as a function of time.

So typically a shear wave front looks like the second and third image above. And the way you would calculate the shear wave speed is just by taking the inverse slope of this wave front. There's several algorithms that you can use to do that. And then that can help you compute the shear wave speed. And if you assume isotropic, linear, elastic, incompressible medium, then you can calculate the Young's modulus.

The second and third figures above are two different spatiotemporal profiles of the shear wave. You can see that the shear wave is traveling faster with time in the 40 kPa medium, which is a more stiff material. And that's because the Young's modulus is proportional to the square of the shear wave speed. So you would see a steeper slope in this wave front in this type of image if you have a stiffer tissue.

Now, a popular transient elastography system, that is clinically used especially for liver fibrosis monitoring, is the system called FibroScan. Now what it does is you have a transducer here, and it's a single element transducer with a vibration capability.

## Transient elastography system



- Most widely used and validated technique for assessment of liver fibrosis

[https://commons.wikimedia.org/wiki/File:FibroScan%C2%AE\\_430\\_Mini.jpg](https://commons.wikimedia.org/wiki/File:FibroScan%C2%AE_430_Mini.jpg)  
Communication Echosens, CC BY-SA 4.0  
<<https://creativecommons.org/licenses/by-sa/4.0/>>, via Wikimedia Commons



So this transducer would vibrate as well as receive the A-mode signals that is coming from your target region of interest. And it has been a validated technique. And you can see that the system is quite portable. You can map the spatial temporal profile of the shear wave. And as well as it outputs the median elastic modulus fairly well, as you can see in the system display.

So there's many research articles in clinical journals as well, demonstrating the feasibility of this technique. and so it's widely studied. The advantage of this technique is that it's quantitative. You can also image deep in the tissue quite well. The liver is more than six centimeters in depth, so this type of technique can image deeper than ARFI-based

techniques. It also allows for real-time imaging and as you can see that the system is quite portable and so it's widely used all over the world.

## **Advantages and limitations of transient elastography**

### **Advantages:**

- Quantitative
- Can image deep in tissue (several cm), deeper than ARFI-based techniques
- Real-time imaging
- Portable

### **Limitations:**

- Operator dependency
- Does not use B-mode image guidance
- Does not create 2-D images
- Assumption of elastic, isotropic, incompressible, homogeneous medium

The limitations of this technique is that it requires a lot on the sonographer's specialization and it's widely operator dependent. This type of technique does not use B-mode image guidance so it depends on the skill of the sonographer to be able to place the transducer at the correct location, that will allow you to image the liver properly or to detect that portion of the liver properly. It does not create two-dimensional elastography maps compared to shear wave elastography and it also assumes an elastic isotropic incompressible homogeneous medium. Despite these limitations, this type of technique is widely used around the world. But there are several articles that look into some limitations of the technique, which the sonographer has to keep in mind.

Another important aspect of shear wave imaging are phantoms. So phantoms are widely used to be able to standardize quantitative measurements from different shear wave elastography techniques and systems. So there are many companies around the world that produce ultrasound systems with the shear wave elastography mode. Each company has their own way to post-process the data. Therefore, the Quantitative Imaging Biomarkers Alliance, or QIBA, this is a committee of the Radiological Society of North America, or RSNA was formed. The goal of QIBA is to be able to develop phantoms that can standardize imaging protocols at different regions around the world.

## Phantoms for shear wave imaging

- Phantoms important for standardizing quantitative measurements from different SWE techniques
- Quantitative Imaging Biomarkers Alliance (QIBA) of the Radiological Society of North America (RSNA)

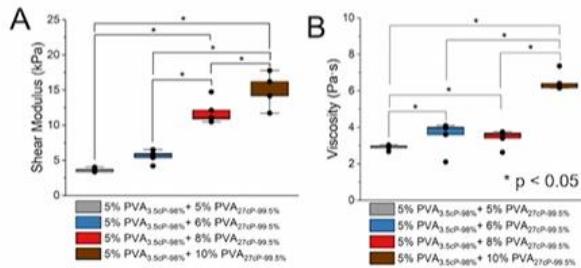



So here I show one such phantom wherein it has typical B-mode imaging targets marked in circles that can help you assess echogenicity of your imaging system, your resolution etc. But this particular phantom also has cylindrical inclusions with different Young's modulus. They are colored in yellow. You can see there's a 10 kPa, a 60 kPa, and a 100 kPa Young's modulus inclusion. And the thing with these inclusions is that they also have different depths. So there's another set that is located at a deeper part of this phantom. And if you take a cross section of this phantom, the cylindrical inclusions actually vary with the different diameters. So this type of phantom will allow a researcher or a system developer to be able to assess the quality of their elastography images. It can also help looking into how well the elastography algorithm will be able to define the boundaries of the inclusions, as well as how small of an inclusion can the elastography image algorithm be able to detect. So phantoms are widely used for those purposes.

Now, the challenge is that tissues are inherently viscoelastic and most calibrated phantoms of known Young's modulus are considered linearly elastic. So there's a drive in the elastography field to be able to develop viscoelastic phantoms. And there are several groups that are developing shear wave viscoelastography algorithms, which will allow you to not only measure the Young's modulus, but also measure the viscosity of the tissue. So this is called viscoelastography. And one such phantom that we are also developing in our lab is made out of polyvinyl alcohol (PVA).

## Viscoelastic phantoms

- Tissues are inherently viscoelastic
- Shear wave viscoelastography
- Polyvinyl alcohol (PVA) material



Images from Sapna R. Bisht, Bhanu Prasad Marri, Jayashree Karmakar, and Karla P. Mercado Shekhar, *ACS Omega* 2024, 9 (7), 8352-8361  
 DOI: 10.1021/acsomega.3c09224 Copyright © 2024 The Authors. Published by American Chemical Society. This publication is open access and is licensed under [CC-BY-NC-ND 4.0](https://creativecommons.org/licenses/by-nc-nd/4.0/).



So this material has been used for decades and we recently found that it has some viscoelastic properties that can be used to assess shear wave viscoelastography algorithms. So here's just an example of what these viscoelastic phantoms would look like. These phantoms you can make in the lab and you can add some cryoprotectant of different colors to make it look like actual tissue. So you can also measure the modulus, and viscosity based on viscoelastography algorithms, according to the recipe or the concentrations of PVA that you are inputting into your phantom.

And this is one such example where figures A and B shows that the viscosity remains fairly constant, but the shear modulus increases as you change the concentrations of the PVA in the phantom. So there are other efforts looking at various types of materials of viscoelastic phantoms to be able to assess the newer viscoelastography algorithms. So I hope this lecture gives you a good overview of shear wave imaging methods. We've talked about how acoustic radiation force impulse as well as mechanical vibration excitation methods will be used to generate shear waves. We also talked about how you can monitor tissue displacements using pulse echo ultrasound, and various speckle tracking algorithms that can help you measure the tissue displacement.



## Summary

- Shear wave imaging methods
- Acoustic radiation force impulse and mechanical vibration excitation methods to generate shear waves in tissue
- Monitor tissue displacements using pulse-echo ultrasound
- Quantify mechanical properties of tissues
- Clinical applications
- Advantages and limitations
- Topics of active research



We talked about how to quantify the mechanical properties of tissues based on several assumptions, as well as different clinical applications that are being done today. There are several advantages and limitations that we've also discussed for each technique. And there are several topics of active research to help improve the technique further and make it more standardized quantitative metrics. So with that, hope you enjoyed this lecture. I will see you in the next lecture.